

## Isolated Tubercular Epididymitis: A 10-Year Series

Shreyas Rai<sup>1</sup>, Abhinav Jogula<sup>1</sup>, Rajendra B. Nerli<sup>1\*</sup>, Ashwin Bokare<sup>1</sup>, Shridhar C. Ghagane<sup>2</sup>, Keyur Patel<sup>1</sup>, Nishant Setya<sup>1</sup>

<sup>1</sup>Department of Urology, JN Medical College, KLE Academy of Higher Education and Research (Deemed-to-be-University), JNMC Campus, Nehru Nagar, Belagavi, Karnataka 590010, India.

<sup>2</sup>KAHER's Dr. Prabhakar Kore Basic Science Research Center, KLE Academy of Higher Education and Research (Deemed-to-be-University), JNMC Campus, Nehru Nagar, Belagavi, Karnataka 590010, India

**Corresponding Author** Rajendra B. Nerli **Email:** rbnerli@gmail.com  
**Received** October 11<sup>th</sup>, 2023  
**Accepted** January 8<sup>th</sup>, 2024

**Abstract** **Introduction:** Genitourinary tuberculosis (TB) is considered a common form of extrapulmonary TB, being second only to lymph node tuberculosis, which is the most common site. Isolated TB of the epididymis is rare, and diagnosis of epididymal TB can be challenging. In this study, we report our series of isolated TB of the epididymis. **Materials & Methods:** We retrospectively collected the outpatient and inpatient records of histologically confirmed epididymal tuberculosis. Data including age, clinical presentation, examination findings, and diagnostic tests were reviewed and analyzed. **Results:** A total of 56 patients were diagnosed to have isolated tuberculosis of the epididymis during the 10-year study period. The mean age was 33 years. The clinical presentation included a hard nodule in the epididymis (100%), hydrocele in 16 (28.5%), posterior scrotal sinus in 6 (10.7%), and sensitivity in 14 (25%) and fever in 3 (5.3%). Four (7.1%) patients had bilateral epididymal nodules, 30 (53.5%) had left-sided, and 22 (39.2%) had right-sided involvement. Scrotal exploration and epididymal biopsy were performed in 16 (28.5%), and unilateral epididymectomy was performed in 40 (71.4%). The histopathological examination revealed a typical tubercular granuloma in all these patients. All patients were put on anti-TB drugs. **Conclusions:** Isolated TB of the epididymis is a rare disease. Treatment with anti-TB drugs remains the first-line intervention in all cases. Surgery is indicated in cases of failure of pharmacological treatment or the development of complications.

**Keywords** Genitourinary tuberculosis; Epididymis; Tuberculosis; Anti-tubercular drugs

### Introduction

Tuberculosis (TB) has been known well since ancient times. References to TB in India have been known since 2000 BC, and indications of lung scarring identical to that of modern-day TB sufferers have been found in preserved bodies. Bayle described genitourinary tuberculosis (GUTB) involving the kidneys, prostate, and testis in 1810. In 1937, Hans Wildbolz (1873-1940) was the

first to use the term ‘genitourinary tuberculosis (1). GUTB has been known to be one of the most common late manifestations of either an earlier symptomatic or asymptomatic pulmonary TB infection. Genitourinary TB is usually secondary to the spread of mycobacteria through the bloodstream during the primary infection. Genitourinary TB frequently occurs five to 40 years after the primary infection.

Extrapulmonary sites account for 10% of TB cases. In India, the incidence of GUTB is nearly about 18% (1,2). Prolonged steroid use and immunosuppressive therapy may increase the risk of reactivation of dormant foci (3). GUTB forms nearly 30% to 40% of all extrapulmonary cases and is second only to lymph node involvement (2,3). Tuberculosis affecting the reproductive system in males can occur at any age; however, it is common in men aged 30–50 years. It is uncommon to see GUTB affecting children as the incubation period is extended. The most commonly involved organs are the epididymis, followed by the seminal vesicle, prostate, testis, and vas deferens (4). Tuberculosis affecting the epididymis alone is very rare (2,5). However, there have been reports that isolated epididymal tuberculosis may be the first or only manifestation of early genitourinary tuberculosis (2,6). In this study, we reviewed our series of isolated epididymis tuberculosis cases.

### **Patients and Methods**

With consent from the University/Institutional ethical committee, the outpatient and inpatient records of histologically confirmed epididymal tuberculosis were collected, reviewed, and analyzed. Age, clinical presentation, examination findings, and diagnostic tests were reviewed and analyzed. The data regarding treatment and outcomes were also noted.

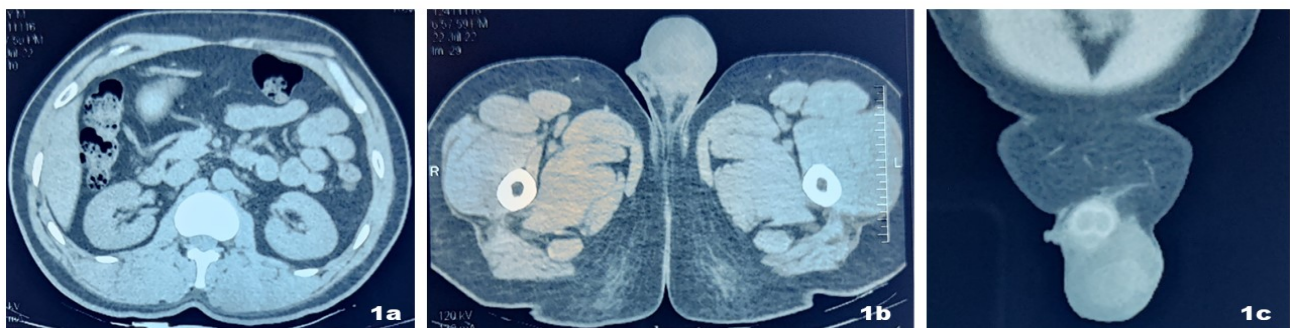Isolated tubercular epididymitis was confirmed by performing a good clinical examination, imaging, and biopsies.

### **Results**

During the study period (January 2012-December 2021), 56 patients were diagnosed to have isolated tuberculosis of the epididymis. The mean age was 33 years. The clinical presentation included a firm nodule in the epididymis (100%), hydrocele in 16 (28.5%), posterior scrotal sinus in 6 (10.7%), sensitivity in 14 (25%), and fever in 3 (5.3%). Four (7.1%) patients had bilateral epididymal nodules, 30 (53.5%) had left-sided affection, and 22 (39.2%) had right-sided involvement. None of the patients had lesions in the prostate on examination. The duration of nodules was 3-11 months. All patients were treated with antibiotics before further evaluation.

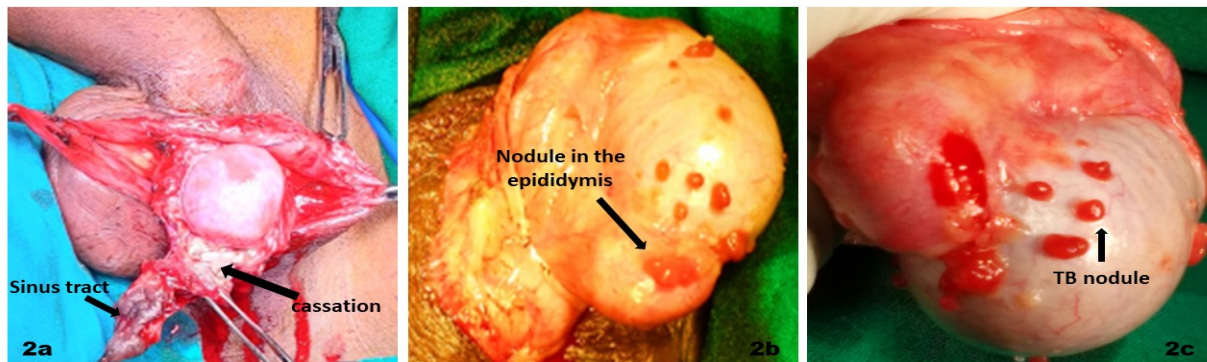
However, none of the nodules responded to routine antibiotics, including roxithromycin, doxycycline, ciprofloxacin, and norfloxacin. None of these patients was diagnosed to have active tuberculosis in the past or had received anti-TB treatment. Eleven (19.6%) patients gave a history of tuberculosis to a family member. All the patients were married, 51 (91%) had children, and three (5.3%) were being evaluated for infertility.

Routine ultrasonography of the kidney, ureter, and bladder regions was performed in all cases. Six (10.7%) patients showed small non-significant renal calculi. The rest of the examination was unremarkable. Computed tomography was done in 38 (67.8%) patients, revealing a normal urinary tract (Figure 1 a, b, c).



**Figure 1.** CT scan of a patient with isolated epididymal tuberculosis showing **a.** Normal appearing kidneys. **b.** Hydrocele of the left testis with turbid contents. **c.** Hydrocele showing thickened tunica vaginalis.

Scrotal exploration and epididymal biopsy were performed in 16 (28.5%), and unilateral epididymectomy was performed in 40 (71.4%) (Figure 2). The histopathological examination revealed a typical tubercular granuloma in all these patients. All patients were put on anti-TB drugs that consisted of isoniazid, rifampicin, pyrazinamide, and ethambutol for 3 months, followed by isoniazid and rifampicin for 6 more months. The patients tolerated the drugs well.



**Figure 2. a.** Exploration of the left epididymitis shows caseation within the epididymis and the scrotal sinus tract. **b.** Nodule seen on the epididymis. **c.** small tubercular nodules are seen on the surface of the testis.

## Discussion

TB spreads to the epididymis either through the hematogenous route or through retrograde extension from the prostate and seminal vesicles (7,8). Infection usually begins in the tail of the epididymis, as it has a higher blood supply and is the first part to be involved in urinary reflux. Isolated epididymal involvement may occur secondary to hematogenous spread. Patients suspected of epididymal TB present with clinical signs and symptoms of scrotal swelling with or without pain, mass, and a discharging scrotal sinus (7,9).

The definitive diagnosis of tuberculosis of the epididymis is by isolating the bacillus from the epididymis. Histopathological examination of the epididymal biopsy may reveal a typical tubercular granuloma. Another way to diagnose TB is by performing the polymerase chain reaction (PCR) test, a fast molecular test with high sensitivity and specificity rates. The treatment of urogenital TB (10) involves a combination of drugs aimed at avoiding bacillary resistance and should be initiated immediately after histological or microbiological diagnosis. At times, one may need to start anti-TB treatment empirically based on clinical, radiological, and laboratory suspect tests (11).

In their study regarding isolated epididymal TB, Viswaroop et al. [6] performed 156 fine needle aspiration cytology specimens, and 108 epididymal biopsies were carried out in 187 men to evaluate chronic epididymal nodules. Fifty-four of the 187 men (median age 32 years) had

tuberculous epididymitis. However, 14 of these were excluded as they had urinary TB as well. None of the 40 men with isolated tuberculous epididymitis had urinary symptoms. Bilateral involvement was seen in five (12.5%) cases. The salient presenting features included painful swelling (16 subjects, 40%), scrotal sinus (4, 20%), and acute epididymitis (2, 10%). The history or concomitant presence of tuberculosis was noted in three subjects each. Anti-TB treatment resulted in a complete response in 10 and a partial response in 18. Five subjects underwent epididymectomy.

Man et al. (12) analyzed the clinical manifestations, diagnosis, and treatment outcomes in 47 patients with epididymal tuberculosis. The average age of the patients was approximately 42 years. The epididymal lesion was seen on the left side in 15 patients (31.9%), right-sided in 22 patients (46.8%), and bilateral in 10 patients (21.3%). The main symptoms were painless swelling of the scrotum in 21 cases (44.7%) and scrotal drop pain in 21 cases (44.7%). Scrotal physical examination revealed epididymal beaded enlargement in 12 patients (25.5%), testicular mass in one patient (2.1%), scrotal tenderness alone in seven patients (14.9%), ill-defined epididymal-testicular border in 21 patients (44.7%) and sinus formation in six patients (12.8%). All patients with anti-TB chemotherapy for 3–6 months. Postoperative follow-up showed an excellent response to treatment.

Isolated TB of the epididymis may be confusing to diagnose at times. Kho et al. (13) reported on a 20-year-old man who presented with a slow-growing painless scrotal tumor for 2 months, with the initial workup suspicious for a right para-testicular tumor. The frozen section of the lesion confirmed the diagnosis of epididymal TB. The patient was put on anti-TB therapy postoperatively for 6 months and had an excellent outcome.

## **Conclusions**

Isolated TB of the epididymis is a rare disease and is often difficult to diagnose. It should be considered as a differential diagnosis in cases presenting with testicular mass. An epididymal infection failing to respond to routine antibiotics should make one suspicious of TB. Treatment with anti-TB drugs remains the first line intervention in all cases of genitourinary TB, and surgery is indicated in cases of failure of pharmacological treatment or development of complications such as abscesses, cutaneous fistulas, or extensive involvement of the epididymis and testis.

### Conflict of interest

The authors declare a conflict of interest as None.

### References

1. Zajackowski T. Genitourinary tuberculosis: historical and basic science review: past and present. *Central European Journal of Urology* 2012; 65:164.
2. Nerli RB, Magdum PV, Pathade A et al. Isolated tuberculosis of the epididymis. *J Communicable diseases*. 2016; 2:91-93.
3. Cek M, Lenk S, Naber KG, et al: EAU Guidelines for the Management of Genitourinary Tuberculosis. *Eur Urol* 2005; 48: 353-362.
4. Yadav S, Singh P, Hemal A, Kumar R. Genital tuberculosis: current status of diagnosis and management. *Translational Andrology and Urology* 2017;6(2):222–233
5. Gueye SM, Ba M, Sylla C, Ndoeye A, Fall A, Diaw J, Mensah A. Epididymal manifestations of urogenital tuberculosis. *Progrès En Urologie Journal De Lassociation Française Durologie Et De La Société Française Durologie* 1988; 8:240.
6. Viswaroop BS, Kekre N, Gopalakrishnan G. Isolated tuberculous epididymitis: a review of forty cases. *Journal of Postgraduate Medicine* 2005; 51:109.
7. Nerli R.B, Sushant Deole, Sreeharsha Nutalpati, Shridhar C Ghagane. Tuberculosis of the prostate in a patient presenting with acute retention of urine: A case report. *Medical Science*, 2020;24(106):4010-4013.
8. Muttarak M, Peh CG, Lojanapiwat B, Chaiwun B: Tuberculous epididymitis and epididymo-orchitis: sonographic appearances. *Am J Roentgenol* 2001; 176:1459–1466.
9. Wallage I, Riley SJ: Tuberculous epididymo-orchitis: the role of ultrasound. *Ultrasound* 2010; 18:195–197.
10. R.B. Nerli, G.V. Kamat, S.B. Alur, Ashish Koura, Prabha Vikram, S.S. Amarkhed, Genitourinary tuberculosis in pediatric urological practice, *Journal of Pediatric Urology*, 2008;4(4):299-303.
11. Madeb R, Marshall J, Nativ O, Ertuk E. Epididimal tuberculosis: case report and review of literature. *Urology*. 2005;65(4):798.
12. Man J, Cao L, Dong Z, Tian J, Wang Z, Yang L. Diagnosis and treatment of epididymal tuberculosis: a review of 47 cases. *PeerJ*. 2020;8:e8291.

13. Kho VK and Chan PH. Isolated tuberculous epididymitis presenting as a painless scrotal tumor, *Journal of the Chinese Medical Association*, 2012;75:292-295.