

## **Incarcerated Inguinal Bladder Hernia: Case Report**

Berk Yasin Ekenci<sup>1</sup>, Huseyin Mert Durak<sup>1</sup>, Ahmet Emin Dogan<sup>1</sup>, Asir Eraslan<sup>2</sup>, Ilkay Guler<sup>3</sup>, Sanem Guler<sup>4</sup>

<sup>1</sup> University of Health Sciences, Ankara Etlik City Hospital, Department of Urology, Ankara, Turkiye

<sup>2</sup> University of Health Sciences, Ankara Diskapi Yildirim Beyazit Training and Research Hospital, Department of Urology, Ankara, Turkiye

<sup>3</sup> General Directorate of Public Hospitals, Ministry of Health of Republic of Turkiye, Ankara, Turkiye

<sup>4</sup> University of Health Sciences, Ankara Etlik City Hospital, Department of General Surgery, Ankara, Turkiye

**Corresponding Author** Berk Yasin Ekenci **Email:** [ekenciberk@gmail.com](mailto:ekenciberk@gmail.com)

**Received** November 22<sup>nd</sup>, 2022

**Accepted** December 28<sup>th</sup>, 2022

**Abstract** The incidence of urinary bladder hernia accompanying inguinal hernias is 1-4%. Herniation of the urinary bladder into the inguinal canal and scrotum can cause urinary retention and hydronephrosis, bladder necrosis, and renal dysfunction. This study presents a case that underwent emergency surgery for an incarcerated inguinal hernia. The hernia sac included the urinary bladder in addition to bowel segments. An attempt to save the ischemic bladder wall during partial bowel resection failed, and the patient developed a vesicocutaneous fistula. The fistula was repaired, and the ischemic bladder wall was resected. During the repair of an inguinal hernia, general surgeons and urologists must be aware of this rare condition and work together in terms of patient management. Although the bladder-sparing approach can be performed in cases without signs of severe bladder ischemia, patients should be followed closely for complications related to ischemia.

**keywords** Urinary bladder hernia, Herniorrhaphy, Inguinal Hernia, Vesicocutaneous Fistula

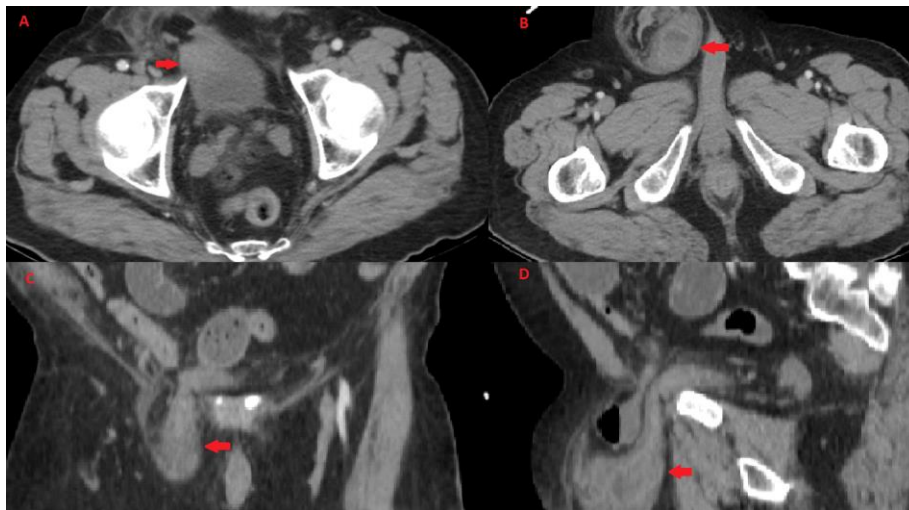
### **Introduction**

Inguinal bladder hernia is a rare clinical condition that Levine described in 1951 as a 'scrotal cystocele' (1). The incidence of bladder hernia accompanying inguinal hernias is 1-4% (2). Most cases are

asymptomatic. Approximately 7% of these patients have signs and symptoms such as difficulty in urinating, pain, and scrotal swelling, which decreases after voiding. Herniation of the urinary bladder into the inguinal canal and scrotum can cause urinary retention and hydronephrosis, bladder necrosis, and renal dysfunction (3). If a bladder hernia is suspected preoperatively, ultrasonography, computed tomography, and magnetic resonance imaging can be performed. However, cystography is the most sensitive imaging method for diagnosing inguinal bladder herniation (4). In this study, we presented a case that underwent emergency surgery for an incarcerated inguinal hernia associated with a urinary bladder hernia.

### Case Presentation

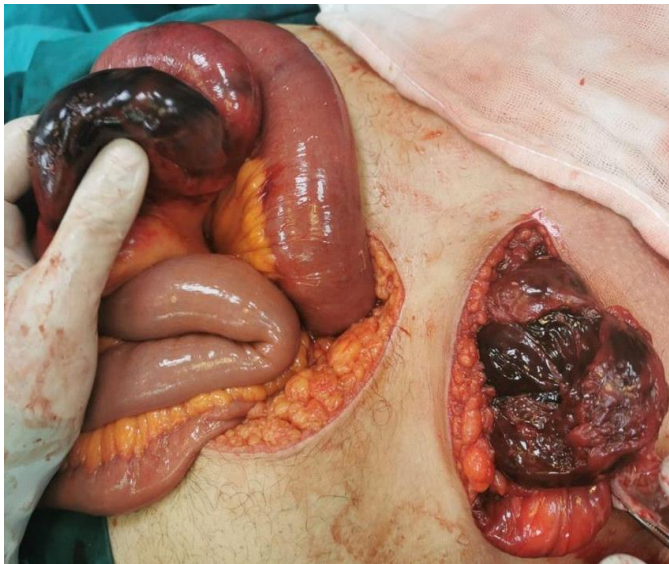
A 63-year-old male patient presented to the emergency department with nausea, vomiting, difficulty urinating, and abdominal pain. The patient did not pass stool for three days and had right hemiscrotal swelling for the last week. The patient had type-2 diabetes mellitus disease and no history of surgery. The vital signs were stable. Physical examination revealed an obese (i.e., body mass index: 31 kg/m<sup>2</sup>) patient with an irreducible inguinal hernia on the right side. There were also diffuse distention and tenderness in the abdomen. The laboratory examination results were unremarkable. An abdominopelvic computed tomography revealed a right inguinal hernia sac, including the urinary bladder wall and bowel loops (Figure 1).



**Figure 1.** Preoperative computed tomography sections. **1A:** Bladder herniated into the inguinal canal in transverse view. **1B:** Bladder and bowel loops herniated into the inguinal canal in computed tomography transverse view. **1C:** Bladder herniated into the inguinal canal in computed tomography coronal view. **1D:** Bladder and bowel loops herniated into the inguinal canal in sagittal view.

There was no dilatation in the pyelocalcical system. The general surgery team decided to proceed with emergent inguinal exploration. The surgery started with an inguinal incision, and the exploration revealed an inguinal hernia sac, including a 10 cm, irreducible bowel segment along with the urinary bladder (**Figure 2**).

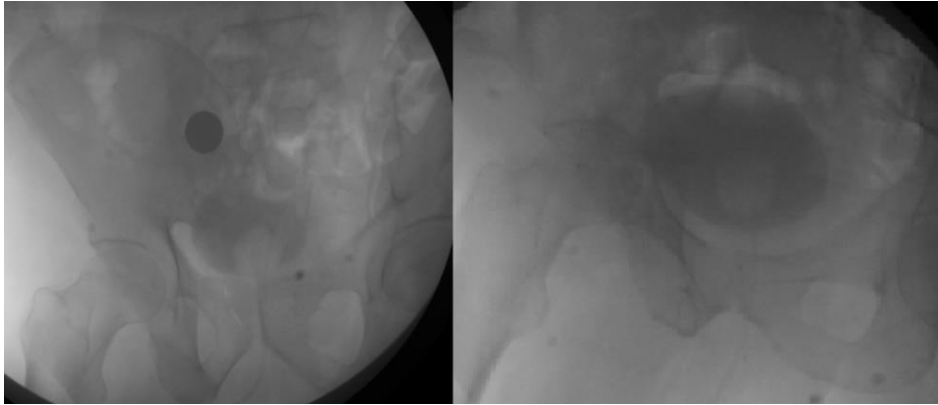
The urology team was consulted intraoperatively, and a median infraumbilical incision was performed. Further exploration revealed herniation of a 10 cm, severely ischemic bowel segment 70 cm proximal to the ileocecal valve. The bladder wall had an ischemic appearance. The severely ischemic bowel segment was resected, and the remaining bowel segments were anastomosed in an end-to-end fashion. The internal ring was expanded, and the herniated, ischemic bladder was reduced to the intraperitoneal space. It was observed that the ischemic area extending from the anterior wall of the bladder to the lateral walls partially improved after reduction.



**Figure 2.** Intraoperative image of the bladder and intestinal loop after reduction

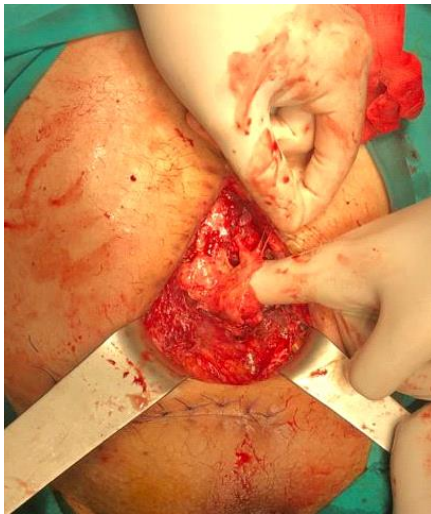A 20F foley catheter was inserted, and the bladder was distended with the administration of 300 cc saline. A bladder perforation was ruled out. The fascia defect starting from the internal ring, was repaired. This repair was performed without a mesh at the suggestion of the urology team. Two rubber tube drains were placed, one into the intraperitoneal space and one into the prevesical space. After referral to the inpatient floor, the patient was followed up with a Foley catheter. His urea, creatinine, and urine output were all in the normal range. The patient was discharged on the seventh postoperative day after removing the drains. The patient's Foley catheter was removed on the tenth postoperative day. As previously scheduled, the patient presented to the urology outpatient clinic two weeks after discharge. There were complaints of

frequent urination and a leak from the surgical incision site. A fistula was suspected, and therefore, a cystogram was performed. The cystogram revealed a vesicocutaneous fistula (**Figure 3**).



**Figure 3.** Extravasation from the anterior of the bladder in the cystogram

The patient was re-admitted, and a Foley catheter was placed. The urine leak was followed for one week; however, it persisted. A fistulectomy was planned. During exploration, a perforation area with a diameter of 1.5 cm and a vesicocutaneous fistula stemming from the anterior wall of the bladder were detected (**Figure 4**).

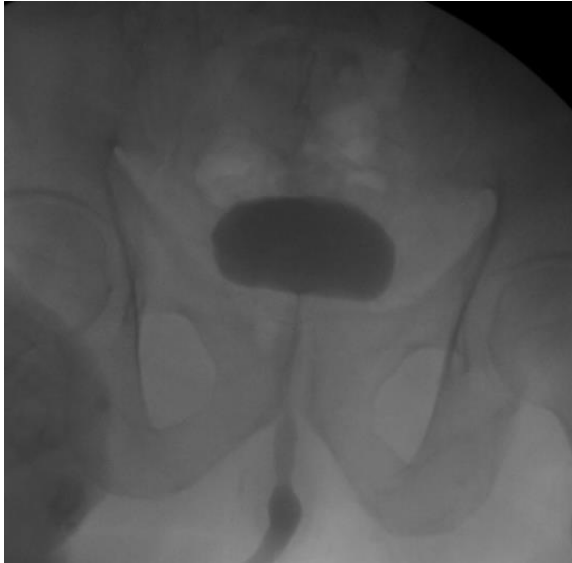

**Figure 4.** Fistula stemming from the anterior wall of the urinary bladder and the perforation site

Necrotic tissues in the bladder wall were debrided. At this stage, approximately 1/3 of the anterior wall of the bladder was excised along with the vesicocutaneous fistula. The bladder was repaired in a water-tight fashion. Administration of 200 ml of normal saline into the bladder did not reveal any urine leak. A tube drain was placed into the perivesical area. The postoperative period was uneventful. The patient was

discharged on the third postoperative day after removing the drain. The Foley catheter was removed on the 10th postoperative day.

No extravasation was observed on the cystourethrogram performed after the postoperative first month (**Figure 5**).



**Figure 5.** Cystogram performed after fistulectomy surgery

Bladder capacity was measured as approximately 250 ml. The patient developed storage symptoms such as frequent urination and nocturia without any obstructive voiding symptoms. Therefore, an anticholinergic (i.e., tolterodine 4 mg tablet, 1x1) medical treatment was initiated. The storage symptoms improved with this treatment without any deterioration in kidney function.

## **Discussion**

Inguinal hernia of the bladder or scrotal cystocele is a rare condition (**5**). It is detected in 0.5-5% of all inguinal hernia cases. The most common risk factors are high body mass index (i.e., >30 kg/m<sup>2</sup>), previous pelvic surgery, and bladder outlet obstruction. It is usually diagnosed in men over 50 and on the right side (**6**). Most cases are asymptomatic and are detected incidentally on radiological imaging or during inguinal hernia repair. Most symptomatic patients have symptoms such as increased voiding frequency, dysuria, and decreased scrotal swelling after voiding (i.e., Mery's sign). In addition, it is associated with prostatic hypertrophy and cystitis in most patients (**2,7**).

If bladder herniation is suspected in a patient, it is suggested that imaging studies such as ultrasonography, computed tomography, or magnetic resonance imaging can be performed (**2,7**). These studies can also

demonstrate the upper urinary tract, prostate, and inguinal region. However, cystography is the most sensitive imaging modality for diagnosing inguinal bladder herniation (4).

It was reported that 77% of inguinal bladder herniations were diagnosed intraoperatively, 7% were detected preoperatively, and 16% were diagnosed during the management of postoperative complications (3,7). Open surgical repair is the preferred treatment method. Surgical technique depends on surgeon preference. Inguinal hernia can be repaired with or without mesh. The most critical aspect of the surgery is the definition of the anatomical content of the inguinal hernia sac. It was reported that the risk of urinary bladder injury could be as high as 12% in cases with preoperatively missed inguinal bladder herniation (7). Also, it was claimed that the rate of bladder injury significantly decreased when bladder herniation was noticed preoperatively (3,7).

Massive incarcerated inguinal bladder herniation is extremely rare. Recognition of inguinal bladder herniation before or during the hernia surgery prevents complications such as hematuria, sepsis, and ureteral injuries in addition to bladder injuries (8). The presence of necrosis, tumor, and diverticulum in the herniated bladder are indications for resection. A midline approach is required to prevent ureteral damage if resection is performed. If an extensive resection is performed, elective bladder augmentation can be planned. The reduction procedure is preferred if resection is not required. In our case, we preferred reduction since there was no necrosis in the bladder wall and the ischemia findings partially subsided during exploration.

Although there was no obstructive uropathy in our case, it was noted that some patients developed upper urinary tract obstruction due to inguinal bladder herniation (4,9,10). In a study about inguinal bladder hernia, Hellerstein et al. denoted that they repaired the inguinal hernia without using a mesh (Bassini technique), and no complications occurred during follow-up (10). They also noted that kidney functions should be evaluated in these patients. If it is necessary, upper urinary tract imaging should be performed in these patients. In line with this suggestion, we assessed the kidney function in our case and showed that it was normal during the preoperative and postoperative periods.

Huerta et al. and Ansari et al. reported that patients with inguinal bladder herniation might also present with macroscopic hematuria (11,12). However, these authors did not find bladder mucosa damage during the cystoscopies of their cases. Also, urinary system imaging did not reveal any finding, such as a stone or tumor, that could cause hematuria. Hernia repair was performed using mesh in both cases, and no bowel or bladder resection was required. Ansari et al. stated that macroscopic hematuria might have occurred due to high intraluminal pressure resulting from urinary retention (11). In our case, there was no hematuria and no urinary retention.

Vindlacheruvu et al. detected incarcerated inguinal bladder herniation in a 79-year-old male patient with right hemiscrotal pain, bowel obstruction, and lower urinary tract symptoms (8). Subtotal cystectomy was

performed due to massive infarction, and a necrotic 5-cm ileum segment was resected. These authors stated that the patient's bladder capacity was 200 milliliters postoperatively. In our case, 1/3 of the anterior wall of the bladder was excised during vesicocutaneous fistula excision, and the bladder capacity was calculated as approximately 250 ml. The patient's lower urinary tract symptoms improved with anticholinergic therapy. In their study, Vindlacheruvu et al. did not give any details regarding how they managed their patient's low bladder capacity.

Helleman et al. presented a 64-year-old man diagnosed with an incarcerated inguinal hernia after complaining of pollakiuria, nocturia, increased pre-existing left hemiscrotal swelling, and left inguinal pain (13). In this case, the bladder fundus was detected in the hernia sac. A portion of the herniated bladder fundus was excised, and hernia repair was performed without bowel excision. These authors stated that no complications occurred during the 6-month follow-up, and the patient's low urinary tract symptoms improved. They also noted that they preferred hernia repair without mesh due to the risk of urinary tract infection, urine leak, and subsequent mesh infection in these cases. In our case, bladder wall excision was not performed during the initial exploration since the bladder walls were not severely ischemic. However, an excision had to be performed after the development of a vesicocutaneous fistula. Since there was no mesh, we did not face any mesh-related complications before and after vesicocutaneous fistula repair and partial bladder resection.

## **Conclusion**

Bladder herniation should be suspected, especially in cases of inguinal hernia accompanied by urinary system tract symptoms. Preoperative diagnosis of bladder herniation can reduce intraoperative and postoperative complication rates. During the repair of an inguinal hernia, general surgeons and urologists must be aware of this rare condition and work together in terms of patient management. Although the bladder-sparing approach can be performed in cases without signs of severe bladder ischemia, patients should be followed closely for complications related to ischemia, such as vesicocutaneous fistula. On the other hand, patients should be informed about the potential need for anticholinergic treatments and bladder augmentation surgeries if an extensive bladder resection is performed.

## **Consent**

Written informed consent was obtained from the patient to publish this case report and accompanying images.

## References

1. Levine B. Scrotal cystocele. *J Am Med Assoc.* 1951 Dec 8;147(15):1439-41.
2. Mohan A, Srinivasan K. Scrotal Cystocele in a Sliding Left Inguinoscrotal Hernia: A Case Report and Review of Literature. *Euroasian J Hepatogastroenterol.* 2017 Jan-Jun;7(1):87-88.
3. Taskovska M, Janež J. Inguinal hernia containing urinary bladder-A case report. *Int J Surg Case Rep.* 2017;40:36-38.
4. Alfraji N, Douedi S, Hossain M. Symptomatic inguinal bladder hernia causes post-renal acute kidney injury: A rare case report. *Ann Med Surg (Lond).* 2020 Sep 28;59:153-155.
5. Branchu B, Renard Y, Larre S, Leon P. Diagnosis and treatment of inguinal hernia of the bladder: a systematic review of the past 10 years. *Turk J Urol.* 2018 Sep;44(5):384-388.
6. Epner SL, Rozenblit A, Gentile R. Direct inguinal hernia containing bladder carcinoma: CT demonstration. *AJR Am J Roentgenol.* 1993 Jul;161(1):97-8.
7. Moufid K, Touiti D, Mohamed L. Inguinal bladder hernia: four case analyses. *Rev Urol.* 2013;15(1):32-6.
8. Vindlacheruvu RR, Zayyan K, Burgess NA, Wharton SB, Dunn DC. Extensive bladder infarction in a strangulated inguinal hernia. *Br J Urol.* 1996 Jun;77(6):926-7.
9. Karanikas M, Kofina K, Foutzitzi S, et al. Urinary bladder-containing incarcerated inguinoscrotal hernia: a case report. *J Surg Case Rep.* 2020 Nov 25;2020(11):rjaa092.
10. Hellerstein LH, Sacks SM, Hellerstein DK. Obstructive uropathy from complete bladder and bilateral ureteral incarceration within an inguinal hernia. *BMJ Case Rep.* 2018 Feb 27;2018:bcr2017222637.
11. Ansari K, Keramati MR, Rezaei Kalantari K, Jafari M, Godazandeh G, Pakzad M. Gross hematuria as the presentation of an inguinoscrotal hernia: a case report. *J Med Case Rep.* 2011 Dec 4;5:561.
12. Huerta S, Fairbanks T, Cinat M. Incarcerated vesicoinguinal hernia presenting with gross hematuria. *J Am Coll Surg.* 2005 Dec;201(6):992-3.
13. Helleman JN, Willemsen P, Vanderveken M, Cortvriend J, Van Erps P. Incarcerated vesicoinguinal hernia: a case report. *Acta Chir Belg.* 2009 Nov-Dec;109(6):815-7.